

# Surgical anatomy of upper arm: what is needed for AVF planning

Surendra Shenoy

Washington University School of Medicine, Barnes Jewish Hospital, St. Louis, MO - USA

**ABSTRACT:** The majority of patients with end-stage renal disease (ESRD) have anatomy suitable for arteriovenous fistula creation. Clinical examination supplemented with duplex Doppler vessel mapping plays a crucial role in evaluation of the anatomy to plan dialysis access in a given patient. Access planning should take into consideration the overall health status and longevity of the ESRD patient on dialysis and potential for the access failure. Accordingly, access planning should involve not only a plan for the initial procedure, but include an algorithm to provide an access sequence to support the patient through the entire ESRD life. (J Vasc Access 2009; 10: 223-32)

**Key words:** Arteriovenous access, Access planning, Arm surgical anatomy, AVF

The adequacy of hemodialysis (HD) depends on the quality and reliability of vascular access. Current data suggests that once successfully created, a well-functioning native vein fistula is the optimal access for HD. Therefore, several programs including the "fistula first" initiative, which embraces the K-DOQI recommendations, concentrate on increasing the arteriovenous fistula (AVF) prevalence in the US (1). Published studies suggest that early fistula failure rates are high and range from 20 to 61% (2-4). It is also evident that the success of AVF creation and maturation, is largely dependent on pre-fistula surgery planning regarding site selection for fistula anastomosis and surgical technique. A thorough understanding of the vascular anatomy is critical in selecting the site for the arteriovenous anastomosis that provides the flow rates necessary for the development of an optimal outflow vein.

The anatomy of the upper extremity arterial and venous system is elegantly described in several anatomic books (5-7). While most of the descriptions are consistent regarding major arteries their branches and their nomenclature; they tend to vary considerably for the location of veins, venous tributaries and their nomenclature. This is likely due to the high variability in venous anatomy and often results in a considerable amount of ambiguity while describing certain operative procedures. There is no literature describing the applied anatomy of upper extremity vasculature that pertains to AVF creation.

This article attempts to outline the surgical anatomy of the upper extremity pertinent to AVF planning and the applied aspect of AVF maturation in end-stage renal disease (ESRD) patients. This article is based on the experience of the author using ultrasound (US) as the primary mapping technique to evaluate the peripheral vascular anatomy for AV access planning in the upper extremity in over 1000 ESRD patients.

## ARTERIAL SITE SELECTION

Arterial inflow is a key component that is necessary for AVF maturation. A native vein fistula that has poor inflow from the artery fails to dilate and develop into a usable conduit for dialysis. The volume of blood flow to the upper limb (at rest) measured in the brachial artery using a duplex Doppler US in patients with ESRD is usually <100 ml/min (mean 6-78 mL/min; mean 31 mL/min). The volume flows in the brachial artery in the same ESRD population with well functioning radio cephalic AVF ranges from 800-1200 ml/min and brachiocephalic fistula 1000-1500 ml/min (8-10). Quality and diameter of the inflow artery play a major role in the ability to dilate and accommodate this 10-25 fold increase in the blood flow (11). This increase in the flow is a result of the body's compensatory mechanisms trying to overcome the acute loss of resistance caused by the creation of a fistulous communication between the artery and the vein in an attempt to maintain the perfusion pressure in the capillary beds, to preserve the viability of the extremity distal to the site of anastomosis. The luminal diameter and the length of the artery plays a major role in determining the volume of blood that could flow through the vessel for a given pressure and viscosity of the blood. Since the length of the vessel is usually unchanged the increase in blood flow in AVF constructed using small sized artery (radial or ulnar) for the inflow, depends on the capacity of the vessel to dilate to increase the diameter, which in turn depends on the quality of the vessel wall (11). This argument is corroborated by the fact that a decrease in resistive indices measured after inducing reactive hyperemia, (a measure of the ability of the vessel wall to dilate) has shown some correlation with AVF maturation (12). Elderly patients with arteriosclerosis (resulting in thick walled arteries) with limited capacity

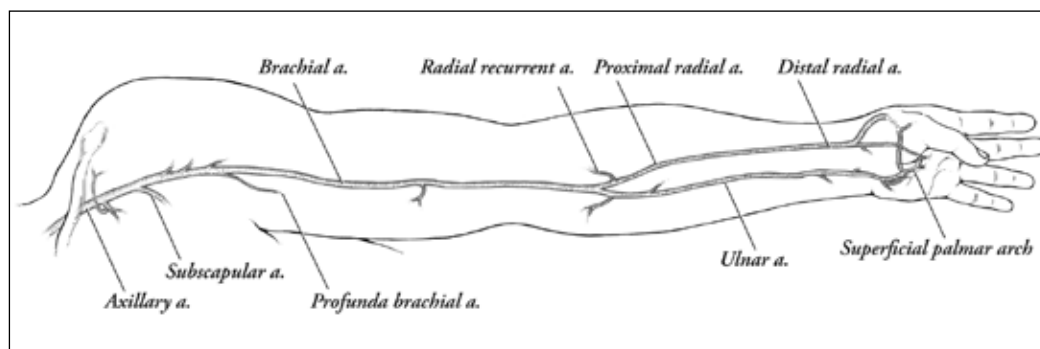


Fig. 1 - Arterial anatomy in the upper limb.

to dilate tend to have lower flows in radiocephalic fistulae. Dilating such arteries (breaking open the stenotic areas) has shown to be beneficial in successful AVF maturation (13). In contrast, fistulae constructed in children with healthy arteries <2 mm in diameter, dilate adequately to provide higher flows underscoring the importance of arterial inflow in fistula maturation. This increase in flow parallels an increase in diameter of the feeding artery (14). The quality of the vessel wall becomes less of an issue for a fistula that relies on large caliber arteries (brachial and larger). In this situation, due to the larger diameter and shorter length, flow is more dependent on the diameter of the vessel which is already large (usually >4 mm) and is capable of handling the increased flow required to overcome the loss of resistance caused by AVF construction. Here, the size of the anastomosis can act as a determinant of the flow. Hence creating a small anastomosis with diameters of 4-5 mm is adequate to provide necessary flow for adequate AVF maturation placing the distal extremity at a lower risk of vascular compromise (15).

Therefore, the quality and diameter of the artery plays a major role in the maturation of the AVF. Evaluation of the anatomy, diameter and the wall quality are critical in vascular access planning to select the site to locate the inflow anastomosis.

#### APPLIED SURGICAL ANATOMY

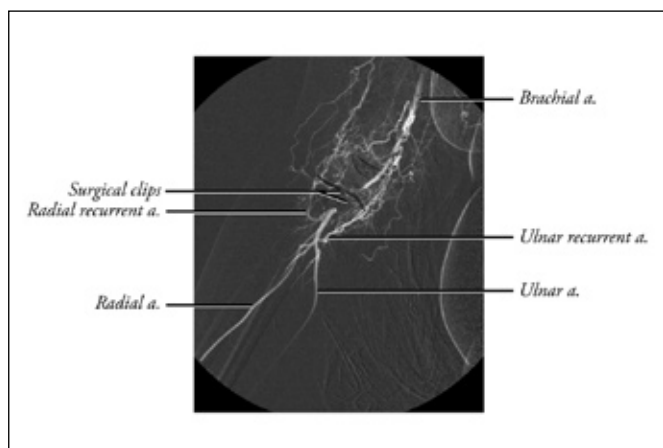
In most patients, the axillary artery, which continues as the brachial artery, is the only source of blood supply to the upper extremity. The axillary artery has several branches. Some of the larger branches, especially the subscapular and occasionally the circumflex humeral, are approachable through an axillary incision (Fig. 1). These branches have been used to obtain inflow in AV graft (AVG) surgery (16). Being relatively narrow, they limit the inflow into the AVG, thereby providing an option to construct access that has a lowered incidence of developing steal symptoms. These branches are visualized and assessed for their suitability with selective angiography as part

of access planning. Axillary artery or its branches are not generally used to obtain inflow for an AVF.

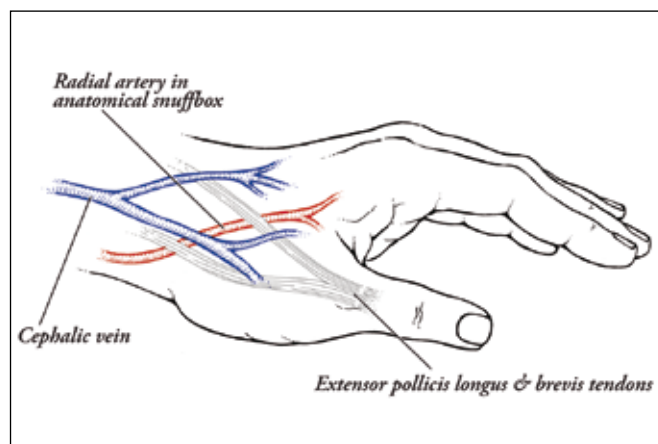
The brachial artery is the continuation of the axillary artery. It exits out of the base of the axilla as a neurovascular bundle covered by the axillary sheath. Other than a profunda brachial artery, all branches of the brachial artery until bifurcation as radial and ulnar arteries are muscular and nutrient branches to the humerus. Many of these branches play a major role in maintaining the collateral circulation around the elbow (Fig. 1). Other than a small decrease in the diameter, there are no major anatomic differences between the axillary and brachial arteries. Clinicians have taken advantage of this proximal larger diameter to treat steal syndrome using proximalization of the inflow (17).

The brachial artery divides into radial and ulnar in the cubital fossa. Often (in 15-20%) this bifurcation could occur higher up anywhere in the upper arm as high up as in the axilla. Using the distal radial artery (DRA) for inflow in such situations could result in failure or delay in fistula maturation due to low flows (long narrow artery). Therefore, it is important to recognize and record this anatomical variation during vessel mapping.

The first few centimeters (3-4 cm) of the radial artery are referred to as the proximal radial artery (PRA). The PRA often has a few muscular branches that supply the flexor muscle heads. Often there is a significant sized branch, the radial recurrent artery, arising in this segment. This branch serves as an important collateral branch in maintaining the circulation to the distal extremity in situations where the main brachial artery is narrowed or interrupted during access surgery (Fig. 2). Therefore, every attempt should be made not to divide the tributaries of the PRA, but rather control them during vascular access surgery. The caliber of the PRA tend to be minimally (a few fractions of a millimeter) larger than the radial artery at the wrist. PRA also tends to have a lesser degree of calcification compared to the DRA. Thus, it often provides a better source for arterial inflow for access created in this area. Due to its narrower diameter (caliber) compared to the brachial artery, blood flow in the radial artery tends to rely more on its length and quality of the vessel wall



**Fig. 2** - Collateral circulation around elbow in a patient with brachial artery ligation during AV access.



**Fig. 3** - Relationship of radial artery and cephalic vein at anatomic snuffbox.

that allows it to dilate. Many authors have reported lesser chances of vascular steal phenomenon when using PRA as an inflow to an AV access (18). It is important to place the anastomosis at least 1.5-2 cm beyond the bifurcation to exploit this anatomic advantage of the caliber as a flow restricting mechanism (19).

The radial artery travels straight down to the wrist giving small muscular branches as well as branches that supply the nerves and joints. These branches are mostly situated posteriolaterally all along its course. It is a good surgical practice not to sacrifice (ligate) any of the radial artery branches unless necessary while creating an AVF. Near the wrist, the radial artery courses dorsally after giving the superficial palmar branch that contributes to the superficial palmar arch (Fig. 1). The caliber of this superficial palmar branch is significantly smaller than the main radial artery. Inadvertent use of this branch for a fistula inflow could be a cause of AVF non-maturation. The distal 4-5 cm of the radial artery before the palmar arch branch is often referred to as the distal radial artery (DRA) in vascular access literature. Though it is commonly used as an inflow vessel near the wrist, the cephalic vein in many patients has a tendency to branch slightly higher (7-10 cm from the wrist crease) and course away from the artery in this area. In such patients, the artery is easily accessible at a higher location in the forearm (between the middle and lower third of forearm) to construct a high forearm DRA to a cephalic vein fistula. This portion of the artery often runs along the medial border of brachioradialis tendon often located in a slightly deeper plain.

At the wrist, the radial artery travels dorsally underneath the antibrachial fascia, underneath the tendons of abductor pollicis longus and extensor pollicis brevis. It is consistently palpable in a depression termed the anatomic "snuff-box", seen between the tendons of extensor polli-

cis brevis and extensor pollicis longus, by extension with slight abduction of the thumb. Though easily palpable, it is always located deep to the tough fascial sheath that covers the tendons and runs on the floor of the snuff-box. The caliber of the radial artery in this location tends to be quite similar (fractions of a millimeter smaller) to that of the radial artery at the wrist. This location also has an advantage in that the cephalic vein often originates in this location, and is situated directly above the artery and requires minimum amount of mobilization for AVF construction (Fig. 3). This area often serves as an excellent location to obtain fistula inflow even in obese individuals. The only anatomic structures that need care during the dissection in this area are the superficial digital branches of the radial nerve (when injured could present with cutaneous anesthesia at the base of the thumb).

The radial artery could be used for the fistula inflow anywhere along its course, though it is often easily accessible in a few specific locations. The most distal location is the anatomic snuff-box. At the wrist, the radial artery is accessible a few centimeters above the wrist crease. This is the most common location for a forearm AVF. It can be used to obtain inflow to the fistula near the wrist or often 8-12 cm higher (high/mid forearm radiocephalic fistula) depending on the proximity of the cephalic vein. The PRA is the other location used to provide the access inflow. The radial artery in this location is commonly used to obtain a restricted inflow (in an attempt to reduce steal) while placing AVGs, as well as for upper arm cephalic or basilic vein based AVF. Occasionally the PRA can be used as an inflow source in creating a reverse flow into the median cephalic vein and upper arm outflow through the lateral cephalic for patients with suitable anatomy (18).

The ulnar artery, the larger of the two terminal branches of the brachial, is seldom used for an AVF inflow. From its origin at the brachial bifurcation it travels po-

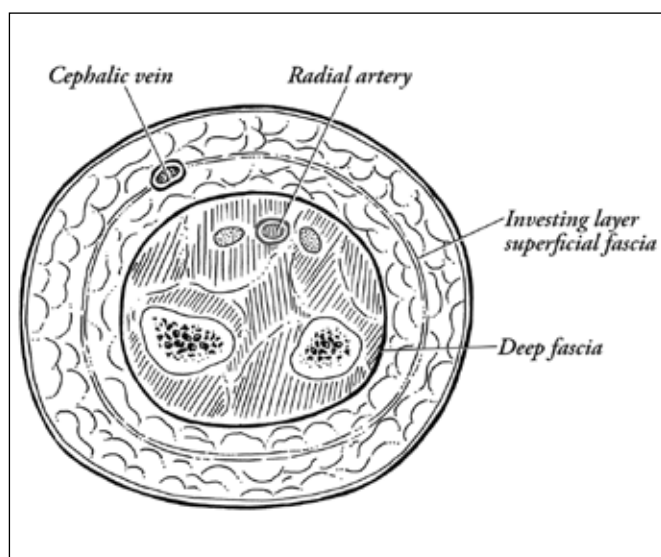


Fig. 4 - Anatomic location of superficial and deep veins.

sterior-laterally and soon gives rise to a large interosseus branch. Beyond this, the ulnar tends to be of a narrower caliber than the radial and travels on the lateral aspect of the forearm. The large proximal branch and the narrow distal caliber may be the reason why fistulae based on ulnar artery inflow are often slow to mature and tend to have lower flows compared to radial artery. Generally, the ulnar artery is deep and is not palpable. It may be palpable in the lower third of the forearm between the tendons of flexor digitorum superficialis and flexor carpi ulnaris in lean individuals.

#### IMPORTANCE OF VEINS IN AV ACCESS

The cannulation segment (CS) (dialysis needle access segment), provided by the outflow vein, is an equally important element as the inflow that is necessary for the successful functioning of the AVF. An adequate CS should be a straight segment of vein that is more than 10 cm long, with a diameter of >6 mm, situated <5 mm beneath the skin surface. If the vein is tortuous one should look for two straight segments each >4 cm (20). To make this concept easy to remember the DOQI recommend the "Rule of 6's" (21). A thorough knowledge of venous anatomy to evaluate and identify a segment of vein that has a potential to develop into an adequate CS (also referred to as fistula conduit) is critical for the planning of an AVF. Most of the superficial veins in the forearm have the capacity to dilate secondary to the increased blood flow resulting from creation of an arteriovenous communication. Veins that have a caliber >2-2.5 mm more consistently tend to dilate and provide a CS that meets the requirements for mature AVF (12, 22). Once again, the quality of the vein wall is

probably the most important factor for vein dilation, not the actual diameter. Vein segments that have been injured due to previous needle sticks or indwelling catheters (peripherally inserted central catheters - PICC) usually fail to dilate. Often, the segment of vein between the stenosis site and the arterial inflow develops wall thickening rather than dilation (possibly due to the stimulation of vein wall smooth muscle by the elevated intravascular pressure resulting in hypertrophy). Therefore, vein dilation seems to be a function of uninterrupted outflow and the quality of the vein wall.

#### APPLIED SURGICAL ANATOMY OF VEINS

Venous return to the upper extremity is provided by two sets of veins namely the superficial and the deep veins. The main superficial veins are superficial to the deep fascia and are often located at or below the investing layer of superficial fascia in the subcutaneous tissue (Fig. 4). Deep veins are situated deep to the deep fascia and often accompany the artery and the nerves supplying the limb forming a neurovascular bundle. Small superficial veins that drain blood into the named main superficial veins are referred to as venous tributaries. Blood flows from superficial veins into the deep veins. This unidirectional flow is aided by the valves within the veins. The major named superficial veins join the deep veins at fairly constant anatomical locations, for example, the cephalic vein joins the axillary vein in the infra clavicular fossa.

In addition to this direct drainage of the named superficial vein into the deep veins, there are several small veins (vein branches) that periodically arise from the superficial venous system and join the deep venous system. These are called the perforating veins (they perforate or travel through a defect in the deep fascia). While some of the perforators can be found at constant locations (for example, the perforating vein at the cubital fossa), the locations of many perforators are inconsistent.

Venous blood flow is a passive flow (not supported by a smooth muscle pump such as the heart). It is assisted to some extent by the peripheral muscle contraction and smooth muscle in the vein wall. The direction of the flow is maintained by the valves within the vein which prevents flow reversal. Location of the valves within the veins is highly variable. They are commonly found in the deep veins near the entry of a tributary. They are also in the tributary close to the site of its entry into the deep vein (Fig. 5). Both these locations have a potential for flow reversal. The reason for the existence of valves in certain other locations cannot be explained. They are usually sparse to absent in larger veins such as the common iliac or central veins such as inferior vena cava.

Valves are semi lunar folds (reduplication) of intima supported by connective tissue and elastic fibers attached

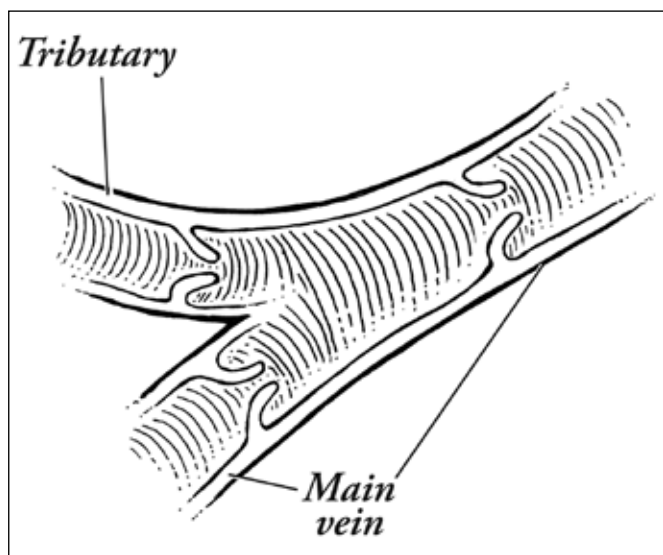


Fig. 5 - Location of valves in the veins.

by their convex base to the vessel wall with concave margins that are free in the lumen of the vein. They are covered on both the surfaces by venous endothelium. Valves usually have two and occasionally one or three cusps. The wall of the vein tends to be thinner and dilated for a short segment beyond the valve giving them a beaded appearance during the low flow state. Sites where the tributaries join and perforating vein originate (for example, cubital fossa and cephalic arch) tend to have multiple sets of valves located in close proximity producing complex anatomy. Valves are often difficult to demonstrate during angiography in a high blood flow system (AVF). Experienced radiologists often use diluted contrast to demonstrate them. Valve anatomy and function is easier to demonstrate with a duplex Doppler US examination with a real time scanning (23).

With the creation of an arteriovenous communication, especially with an AVF, valves often tend to be the sites of the development of mid access and outflow problems. The increased blood flow resulting from AVF creation causes the outflow vein to dilate. The dilating vein causes stretching of the valve base precipitating valve dysfunction. Careful clinical examination (for example, pulse leading to thrill in an outflow vein) combined with real time US scanning can demonstrate this early valve dysfunction. These stretched valves are less mobile and produce intraluminal flow obstruction. Due to the high flow and shear stress, they also develop inflammatory changes (thickening often referred to as myxoid degeneration by pathologists) which in turn can lead to fibrosis and eventually the development of stenosis of the vein wall. A combination of altered flow, increased pressure and inflammation; all triggered by intraluminal obstruction caused by a dysfunctional valve, results in a plethora of problems including

neo-intimal hyperplasia. Often the problem may not be of a magnitude that allows progression but can linger as chronic low grade obstruction. Such stenosis can increase the pressure within the needle access segment (pressure is a function of volume flow and diameter of the stenotic outflow). Such fistulae often present with slowly progressing aneurysms of the needle access area, as the healing tissue from a needle stick becomes stretched due to the high pressure in the vein. Though not well documented, many experienced vascular access surgeons routinely destroy any valves they come across in the operative field.

Competent valves within tributaries that join the main AVF outflow vein prevent the reflux of blood from the fistula outflow vein into these tributaries. This produces stasis of blood in some of the tributaries resulting in thrombosis and eventual scarring down the tributaries. The inflammatory response from thrombosis could result in variable amounts of structural alteration in the main outflow vein. Often these thrombosed tributaries act as an anchoring point resulting in the development of tortuosity of the dilating outflow vein of the AVF.

In the absence of competent valves, the tributaries could act as collaterals with the reversal of flow. Occasionally these tributaries could serve as (or replace) the main vein in situations where the main vein has thrombosed or is chronically obstructed. Such tributaries can serve as suitable conduits for AVF. Such collaterals can also serve as a good source for autologous veins that can be used to reconstruct the area of stenosis in the main outflow to help AVF mature.

Occasionally, the main veins can divide or give rise to branches (for example, the cephalic vein in the forearm continuing as the lateral cephalic and median cubital branch). While planning an AVF, it is important to distinguish a tributary from a branch of the main vein. The tributary drains into the main vein and the vein branch carries the blood flow out of the main vein. Since valves open in the direction of the flow, valves have to be incompetent for a tributary to act as an outflow. Similarly, any valve in a vein branch has to be rendered incompetent to obtain a reversal of blood flow direction. Certain vein tributaries and branches that are consistently present such as the median cephalic vein have been exploited by surgeons to create AVF conduits by reversing the blood flow by destroying the valves within them (18).

#### APPLIED SURGICAL ANATOMY

Most of the AVF constructed as primary options for dialysis rely on superficial veins in the forearm or the upper arm to provide the needle access segment, i.e. the cephalic and the basilic veins. The deep venous system in the upper extremity is often reserved as a secondary

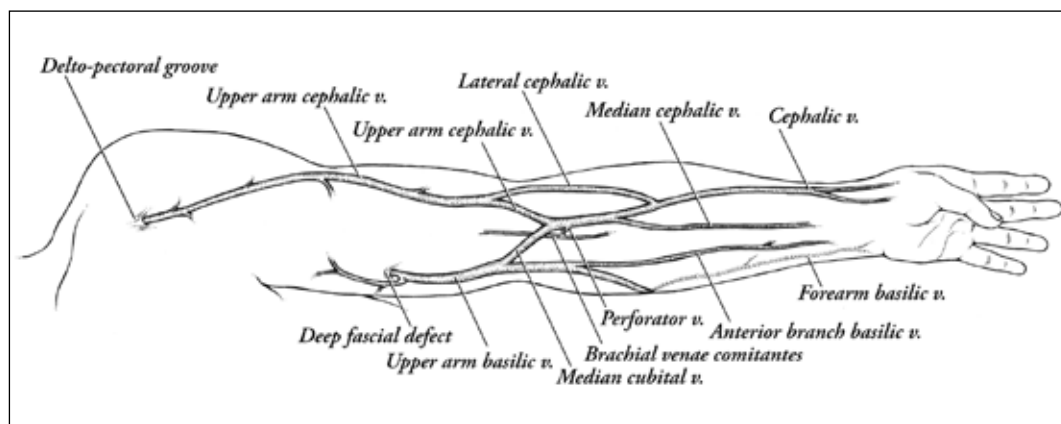


Fig. 6 - Venous anatomy in the upper limb.

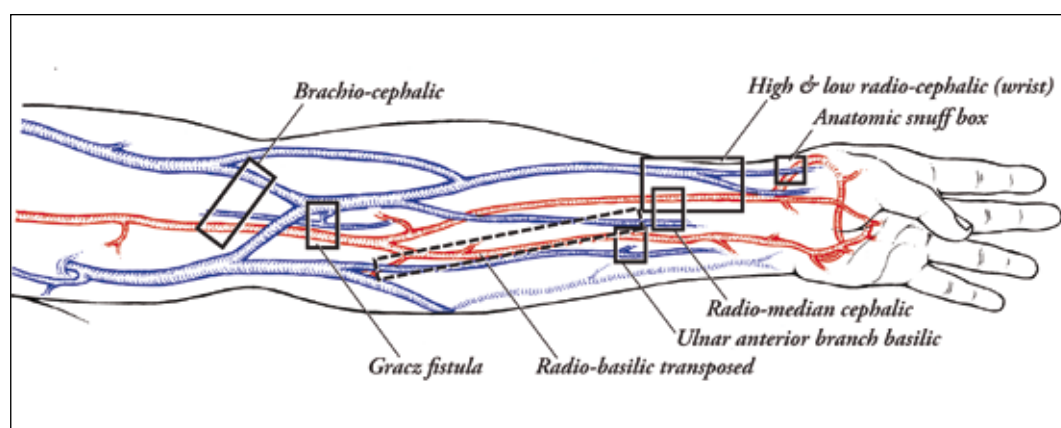


Fig. 7 - Primary sites of AVF creation.

option in AVF planning for those patients who have failed the primary options and are candidates for more complex access planning.

#### THE CEPHALIC VEIN

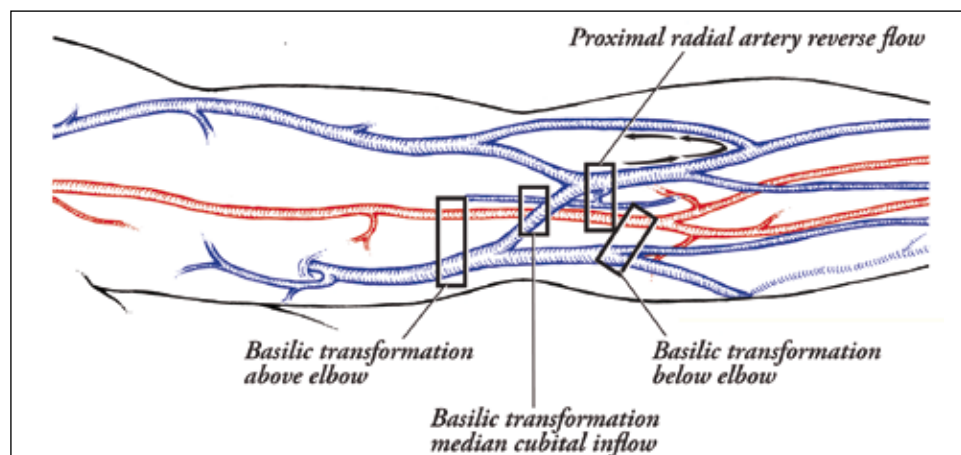
The cephalic vein originates in the web space between the thumb and the index finger. It often has a fairly constant position near the anatomic snuff-box between the tendons of extensor pollicis brevis and extensor pollicis longus (Fig. 3). The radial artery runs directly underneath the vein providing an excellent opportunity to create an AVF requiring minimum dissection and mobilization (24). This is an anatomically relevant aspect for AVF planning that needs to be documented during the vessel mapping procedure.

The cephalic vein travels further on to the anterio-lateral aspect of the forearm at the level of the wrist where it usually runs parallel to the radial artery (site where Dr. Appell created the first side-to-side AVF (25)) usually within a centimeter for a variable distance (4-5 cm length) and is joined by a tributary that often drains medial aspect of the back of the hand. This dorsal tributary of the cephalic vein can often be the major component of the cephalic vein. When the dorsal tributary is the ma-

ior component of the cephalic vein it is observed very well on the posterior-lateral aspect of the hand (using this vein on the back of the hand for venipuncture saves rest of the cephalic venous system for access creation in ESRD patients). The junction of this prominent dorsal tributary to the main cephalic vein is usually located 7-10 cm from the proximal wrist crease (Fig. 6). The cephalic vein at this junction has a larger caliber and tends to lie closer towards the upper part of the DRA. This is a very useful site to plan the fistula anastomosis to take advantage of the larger caliber of the vein and the artery. This is often termed as the high forearm or mid forearm radio cephalic fistula.

The cephalic vein continues further in the superficial fascia medially towards the cubital fossa where it lies almost directly anterior to the line of the PRA (the artery is deep to the deep fascia). At the junction of the middle and upper third of the forearm, the cephalic vein often has a lateral branch that travels on the lateral aspect of the elbow and joins the upper arm cephalic vein in the lower third of the upper arm. This branch is referred to as "accessory cephalic" in major anatomic text books (5); it is also referred to as the main cephalic vein by some, thus leading to significant confusion. To provide a clinically relevant terminology we refer to this branch as the lateral cephalic branch (Fig. 6). When present, this branch

**Fig. 8** - Secondary sites for access planning.



can serve as the outflow for a PRA based reverse flow AVF where the inflow is obtained through the medial branch and directed into this vein by rendering the valves incompetent. This branch also provides an additional outflow for upper arm brachiocephalic fistula and often helps the fistula stay open when there is an obstruction of the main outflow vein.

Near the cubital fossa, the forearm cephalic vein branches into the median cubital vein and the upper arm cephalic vein. There is a constant perforating vein at this branch point, or in its vicinity, that pierces the deep fascia and the bicipital aponeurosis to join the deep brachial venae comitantes (Fig. 6). It is also joined by a vein of variable caliber, from the volar aspect of the forearm, termed as the median cephalic vein (also termed as the median antibrachial vein) (6). Often this can be more prominent than the cephalic vein and occasionally be the main vein in the forearm. In such situations, it can be used as an AVF conduit with the DRA providing the inflow (Fig. 7). Due to the presence of collaterals, branches and tributaries within a small area, it is quite common to encounter intravenous bands, hypertrophied valves and thrombosed small veins in this region (possibly secondary to previous venipunctures or due to valve inflammation). It is also not unusual to encounter a narrow or absent upper arm cephalic vein and have the majority of the forearm cephalic vein blood flow continue into the median cubital vein. Occasionally the median cubital and the upper arm cephalic may be small or obliterated, and all the forearm cephalic vein blood flow can go into the deeper vein through the perforating branch. It is important to note the anatomy and flow pattern in the veins of the cubital fossa during preoperative vessel mapping.

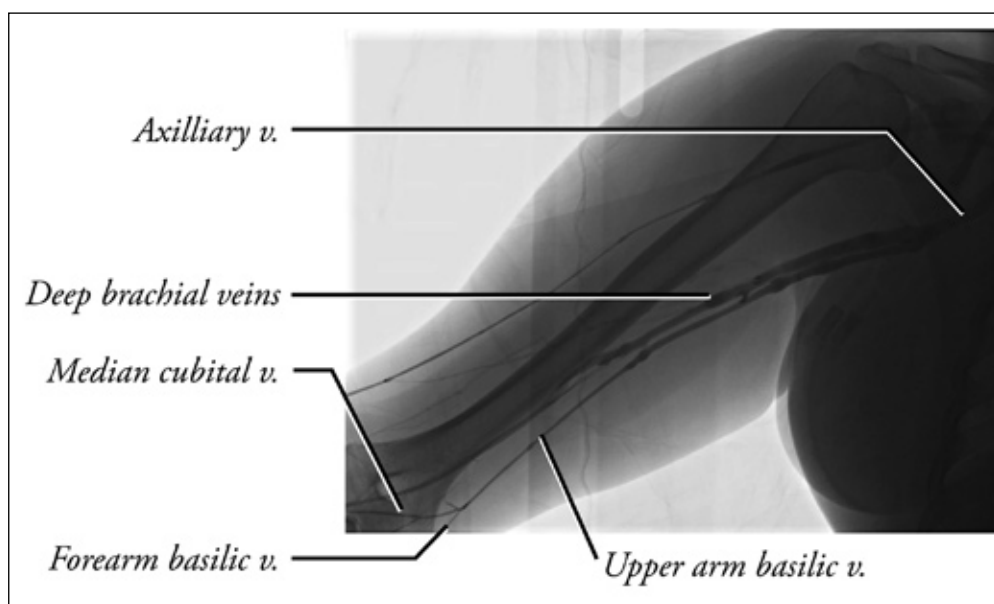
The median cubital vein travels above the elbow towards the medial aspect of the lower third of the upper arm where it joins the basilic vein. Occasionally, it may join the brachial venae comitans in this area. Once again, it is important to evaluate this anatomy. When the median cubital vein joins the upper arm basilic vein, it can serve

as an excellent source of inflow for a basilic transposition fistula (Fig. 8). In this situation, it is easy to perform an anastomosis between the median cubital vein and the brachial artery (below or above the cubital crease) as the vein is situated directly above the artery (the vein is in the superficial fascia and the artery is deep to the deep fascia).

The cephalic vein in the lower and mid third of the upper arm runs on the anterior lateral aspect along the lateral border of the biceps. In the upper third it lies in the deltopectoral groove as it travels around the shoulder to the infra clavicular fossa. Here it dips behind the clavicular head of the pectoralis major and joins the axillary vein after piercing through the clavipectoral fascia. The portion of the cephalic vein that dips down in the infraclavicular region is referred to as the cephalic arch in vascular access literature. As it dips down the cephalic vein is crossed by the thoracoacromial artery and its branches. Lateral and medial pectoral nerves can also cross it. It also receives a few vein tributaries and possesses valves. The combination of these anatomic variables renders the cephalic arch vulnerable for the development of stenotic problems in the setting of high flows resulting from AVF (26). Surgeons need to be well versed with the anatomy in this area, which is relatively simple and is easily approachable for the surgical correction of this problem.

#### BASILIC VEIN AND AVF CREATION

The basilic vein is a superficial vein in the forearm. It originates in the ulnar aspect of the dorsal venous network of the hand near the wrist. As it travels on the posterior aspect of the ulnar side of the forearm in the mid and lower third, it often receives couple of communicating branches from the cephalic vein. These communicating branches often divert the flow from the cephalic vein to the basilic vein in the presence of stenosis or occlusion of the cephalic vein higher up along its course. A con-



**Fig. 9** - Basilic vein anatomy ideal for transposition as a primary procedure.

stant communication behind the wrist can occasionally be exploited to plan a reverse flow fistula. The basilic vein runs on the medial aspect of the upper part of the forearm as it approaches the elbow. At the level of the elbow, it is always anterior to the medial epicondyl (important landmark to locate the basilic vein during difficult vein mapping with US). In the lower third of the upper arm, the basilic vein often has a reasonable caliber (3-4 mm) but is well masked by subcutaneous fat. In this location it is joined by the median cubital vein (Fig. 6). As it travels higher, it pierces the deep fascia and becomes a deep vein that accompanies the brachial artery and usually joins the deep brachial venae comitans in the mid upper arm. In this classic anatomic configuration, the basilic vein becomes less suitable to construct a basilic transposition fistula as a first surgical option. Transposing the basilic vein in this setting means transposing the deep venous system in the upper arm. Failure of this procedure, due to the development of a "swing point stenosis", could result in the obliteration of the deep venous outflow to the upper extremity. This places the limb at a higher risk for venous hypertension with any other kind of peripheral access, thus limiting the further access options. However, in many patients the basilic vein may continue as an independent deep vein and join the brachial venae comitans or the axillary vein near the axilla (Fig. 9). US evaluation can easily recognize this anatomic variation. This anatomy is ideal for attempting a basilic transposition fistula even as a first surgical option in the upper arm. In the event of fistula failure, it still spares the deep veins of the upper arm for future distal access options. It is therefore important to document this anatomical fact that has a direct bearing in surgical planning during US vein mapping. Occasionally in a lean patient, the basilic vein may appear very super-

ficial and easily accessible in the upper arm. However, being a deep vein it often has a tendency to run as a neurovascular bundle along with the artery and nerves. Hence, it is always a prudent practice to transpose the basilic vein prior to clearing it for needle access regardless of the depth and size.

The basilic vein in the forearm does not provide an easily accessible conduit in its normal anatomic location. However, a large basilic vein can be transposed anteriorly to obtain an inflow from the radial artery to construct a forearm radio basilic AVF (Fig. 7). Occasionally one can find a dominant anterior tributary (or a dominant median vein of the forearm) joining the basilic system near the elbow. When present this branch in the forearm can be used as the access conduit by anastomosing it to the ulnar artery (Fig. 7).

In the author's experience, ulnar artery based fistulae tend to have lower flows and can take longer to mature.

#### ANATOMIC BASIS FOR ACCESS PLANNING

The evaluation of the anatomy using a duplex US probe is an extremely useful technique to map the peripheral arteries and veins. The real time mapping should be viewed by the operating surgeon to decide on the vein segment that has the potential to develop into an adequate cannulation segment and determine the site on the artery that could be used to create the anastomosis to obtain the flow required for AVF maturation. Vessel mapping is also helpful to determine the location of the incision that would permit the dissection necessary for fistula creation.

Figure 7 depicts the common locations that need be explored during vessel mapping to determine the feasibility

lity of AVF creation. Some of the primary options for AVF creation include:

- 1) anatomic snuff-box fistula;
- 2) radiocephalic fistula at the wrist;
- 3) high distal radiocephalic fistula;
- 4) PRA to upper arm cephalic (necessitates ligation of the perforator to prevent flow diversion, also may necessitate ligation of the median cubital - useful for a few patients who are at high risk for steal);
- 5) brachiocephalic fistula above the elbow;
- 6) Gracz fistula (27) (original procedure used a deep vein cuff. Since then it has been modified by Konner et al (28) to preserve the deep venous system and reduce steal);
- 7) median cephalic to radial artery fistula;
- 8) anterior branch basilic to ulnar artery;
- 9) Forearm radio basilic fistula with transposed basilic vein.

Failure of the AVF to mature following most of these procedures (except 4 and 6) results in the loss of a single site and vein. In most circumstances, only a segment of a superficial vein is lost. This leaves the remaining access options intact. Hence, during access planning, these procedures should be considered as primary options for AVF creation. Vessel mapping should also evaluate the upper arm basilic vein anatomy. Basilic transposition can be offered as a primary option when the basilic vein travels as an independent vein in the upper arm (Fig. 9).

Surgeons often encounter patients who have failed previous access attempts. A thorough understanding and evaluation of the anatomy of the forearm and upper arm vessels helps to plan complex AVF procedures in such patients. Patients who have exhausted all the forearm superficial and deep vein based access may be candidates

for more complex AVF procedures (Fig. 8) or "secondary options". These include:

- 1) proximal radial artery based reverse flow fistula (occasionally a good option for a patient who is at high risk for steal - safer than options (6) and (7), above);
- 2) basilic transposition with median cubital to brachial artery anastomosis for inflow;
- 3) basilic transposition using forearm basilic to PRA or brachial artery below elbow inflow;
- 4) basilic transposition using the basilic vein above the elbow to obtain brachial artery inflow;
- 5) perforating vein to brachial artery anastomosis (this should be reserved only for those patients who do not have any usable veins in upper extremity and performed with an intention to obtain venous dilation of one of the outflow veins). This procedure should be avoided in patients who have large patent upper arm cephalic and basilic veins. When offered to such patients, this procedure often results in either a high flow fistula or non-maturation of either of the veins. A secondary procedure to salvage such an AVF requires ligation or obliteration of one of the two veins to divert all the flow into the other, thereby jeopardizing the venous real estate that is critical for ESRD patients.

**Conflict of interest statement:** None.

Address for correspondence:  
Surendra Shenoy M.D., Ph.D.  
Section of Abdominal Organ Transplantation  
Campus Box 8109  
660 S. Euclid Ave.  
St. Louis, MO 63110 - USA  
shenoy@wudosis.wustl.edu

## REFERENCES

1. ESRD Networks results: 2002-2006 prevalent hemodialysis access. Accessed 6/06: [www.fistulafirst.org](http://www.fistulafirst.org)
2. Huijbregts HJ, Bots ML, Wittens CH, et al. Hemodialysis arteriovenous fistula patency revisited: results of a prospective, multicenter initiative. *Clin J Am Soc Nephrol* 2008; 3: 714-9.
3. Allon M, Robin ML. Increasing arteriovenous fistulas in hemodialysis patients: problems and solutions. *Kidney Int* 2002; 62: 1109-12.
4. Dember LM, Kaufman JS, Beck GJ, et al. Design of the dialysis access consortium (DAC) clopidogrel prevention of early AV fistula thrombosis trial. *Clin Trials* 2005; 2: 413-22.
5. Johnson D, Collins P, Healy JC, et al. In: Standring S, ed. *Gray's anatomic basis for clinical practice*. Elsevier, Churchill Livingstone, 40th edn, 2008; pp 775-906.
6. Moore KL. Upper limb. In: Moore KL, Dalley AF, eds. *Clinically oriented anatomy*. Lippincott, Williams & Wilkins, 5th edn, 2006; pp 726-884.
7. Pansky B. Upper extremity. In: Pansky B, ed. *Review of gross anatomy*. McGraw Hill, 6th edn 1996; pp 231-324.
8. Shenoy S, Middleton WD, Windus D, et al. Brachial artery flow measurement as an indicator of forearm native fistula maturation. In: Mitchell L Henry, ed. *Vascular Access for Hemodialysis VII*. W.L. Gore and Associates, Precept Press, 2001; pp 233-239.
9. Davidson J, Chan D, Dolmatch B, et al. Duplex ultrasound evaluation for dialysis access selection and maintenance: a practical guide. *J Vasc Access* 2008; 9: 1-9.
10. Wiese P, Nonnast-Daniel B. Colour Doppler ultrasound in dialysis access. *Nephrol Dial Transplant* 2004; 19: 1956-63.

11. Ku YM, Kim YO, Kim JI, et al. Ultrasonographic measurement of intima-media thickness of radial artery in pre-dialysis uremic patients: comparison with histological examination. *Nephrol Dial Transplant* 2006; 21: 715-20.
12. Malovrh M. Native arteriovenous fistula: preoperative evaluation. *Am J Kidney Dis* 2002; 39: 1218-25.
13. Raynaud A, Novelli L, Bourquelot P, Stolba J, Bevssen B, Franco G. Low-flow maturation failure of distal accesses: treatment by angioplasty of forearm arteries. *J Vasc Surg* 2009; 49: 995-9.
14. Lomonte C, Casuci F, Antonelli M, et al. Is there a place for duplex screening of brachial artery in the maturation of arteriovenous fistulas? *Semin Dial* 2005; 18: 243-6.
15. Konner K. Initial creation of native arteriovenous fistulas: surgical aspects and their impact on practice of nephrology. *Semin Dial* 2003; 16: 291-8.
16. Jendrisak MD, Anderson CB. Vascular access in patients with arterial insufficiency. Construction of proximal bridge fistula based on inflow from axillary branch arteries. *Ann Surg* 1990; 212: 187-93.
17. Thermann F, Wollert U. Proximalization of the arterial inflow: new treatment of choice in patients with advanced dialysis shunt associated steal Syndrome? *Ann Vasc Surg* 2008 Oct 28. [Epub Ahead of print].
18. Jennings WC. Creating arteriovenous fistulas in 132 consecutive patients: exploiting the proximal radial artery arteriovenous fistula: reliable, safe, and simple forearm and upper arm hemodialysis access. *Arch Surg* 2006; 141: 27-32.
19. Minion DJ, Moore E, Edean E. Revision using distal inflow: a novel approach to dialysis-associated steal syndrome. *Ann Vasc Surg* 2005; 19: 625-8.
20. Shenoy S. Innovative surgical approaches to maximize arteriovenous fistula creation. *Semin Vasc Surg* 2007; 20: 141-7.
21. Clinical practice guidelines and clinical practice recommendations for vascular access, update 2006. Guideline 1. Initiation of dialysis [cited 2007; available from: [www.kidney.org/professionals/KDOQI/guideline.cfm](http://www.kidney.org/professionals/KDOQI/guideline.cfm)
22. Mendes RR, Farber MA, Marston WA, et al. Prediction of wrist arteriovenous fistula maturation with preoperative vein mapping with ultrasonography. *J Vasc Surg* 2002; 36: 460-3.
23. Wellen J, Shenoy S. Ultrasound in vascular access. In: *Vascular Access: Principles and Practice*. Wilson SE, ed. Philadelphia, PA: Lippincott Williams & Wilkins, 5th edn, 2009: pp 234-242.
24. Sekar N. Snuff-box arteriovenous fistula. *Int Surg* 1993; 78: 250-1.
25. Appell KC. The peripheral subcutaneous arteriovenous fistula. In: Sommer BG, Henry ML, eds. *Vascular Access for Hemodialysis*. WL Gore, 1989.
26. Shenoy S. Cephalic arch stenosis - surgery as first line of treatment. *J Vasc Access* 2007; 8: 149-51.
27. Gracz KC, Ing TS, Soung LS, Armbruster KFW, Seim SK, Merkel FK. Proximal forearm fistula for maintenance hemodialysis. *Kidney Int* 1977; 11: 71-4.
28. Konner K, Hulbert-Shearon TE, Roys EC, Port FK. Tailoring the initial vascular access for dialysis patients. *Kidney Int* 2002; 62: 329-38.