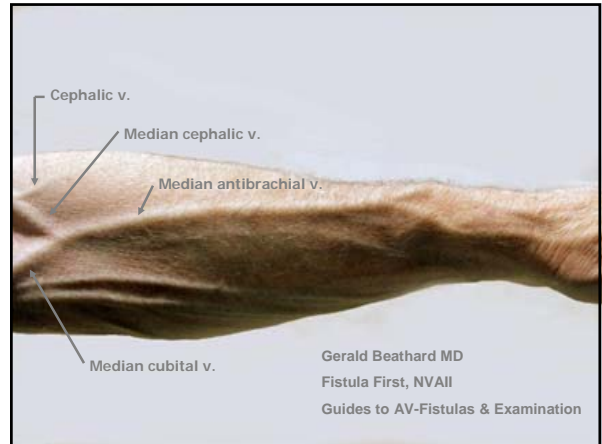




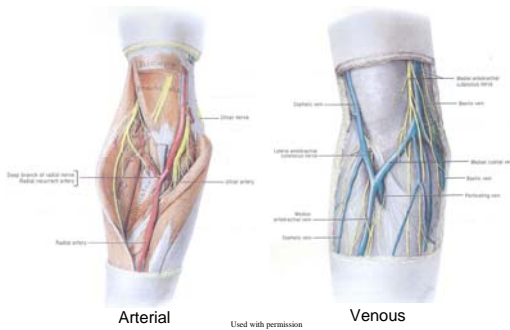
AV Fistulas in Most (All?) Patients: Exploiting the Proximal Radial Artery



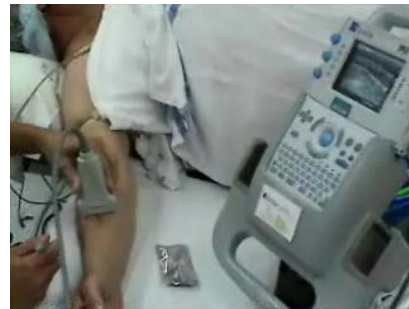William Jennings, M.D. FACS
Associate Professor, Department of Surgery
Mary Louise Todd Cardiovascular Chair



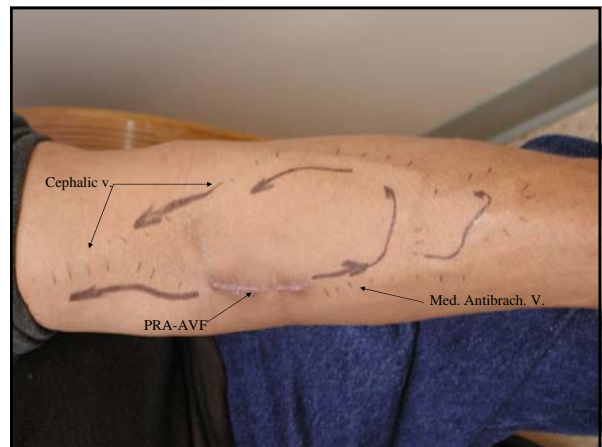
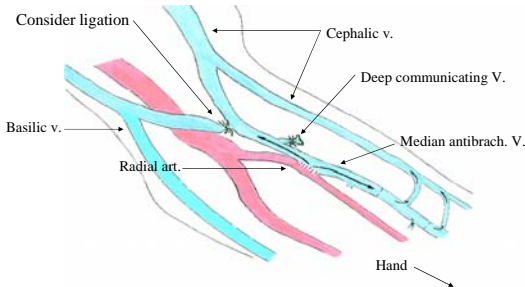
Cubital Fossa

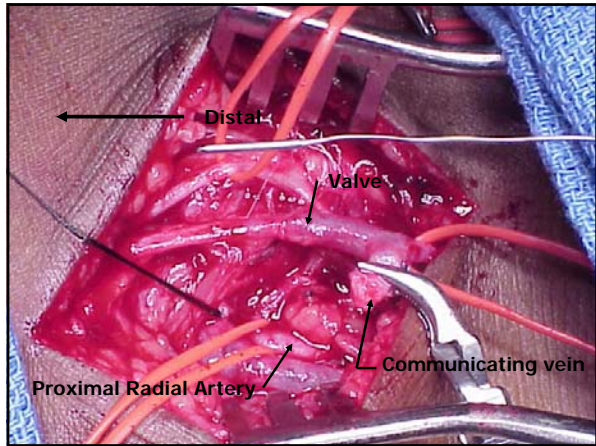


Pre-operative mapping

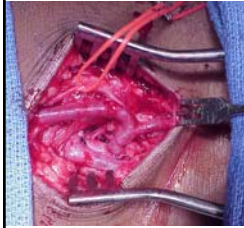


Proximal radial artery AVF

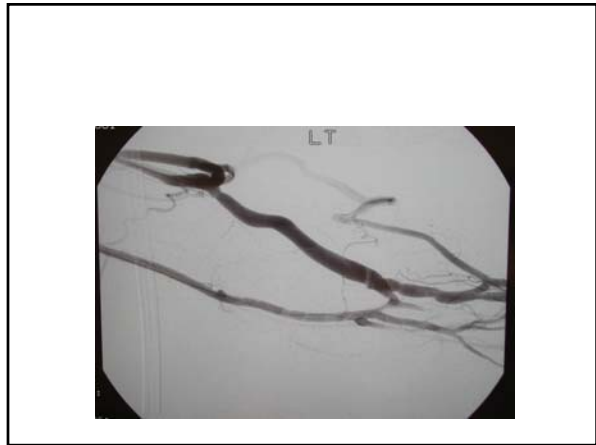



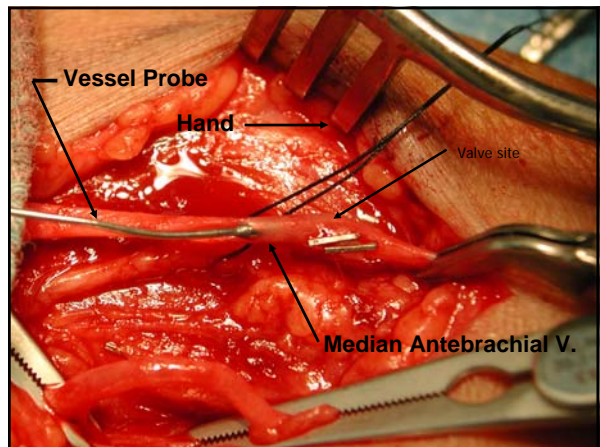
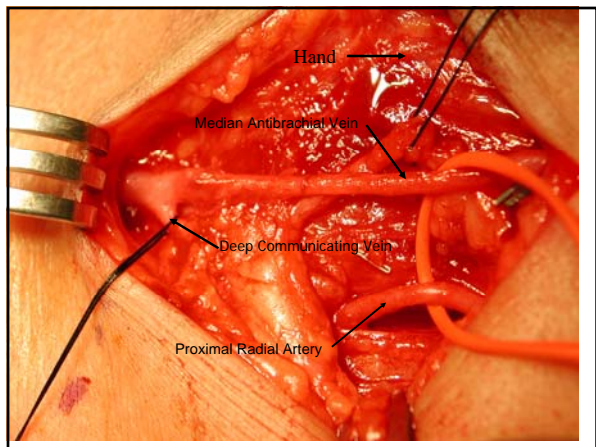
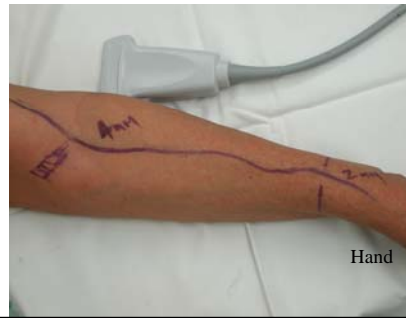Proximal Radial Artery AVF

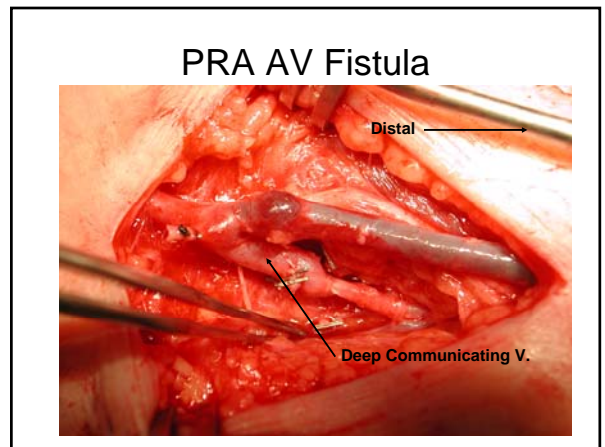
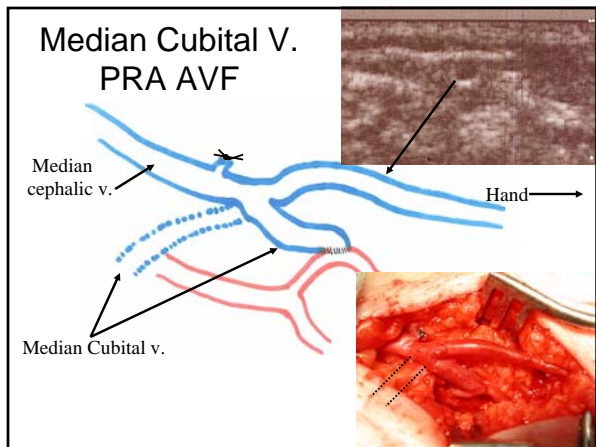
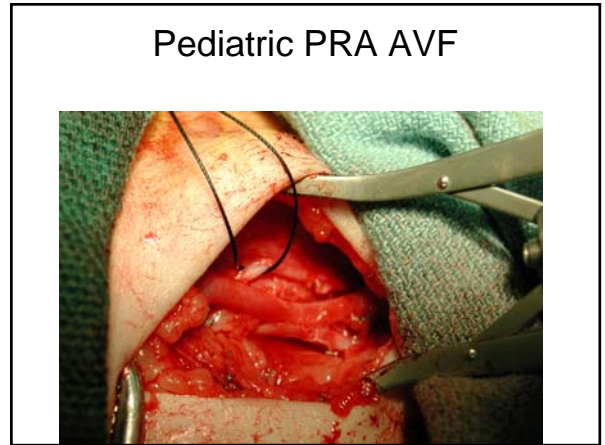
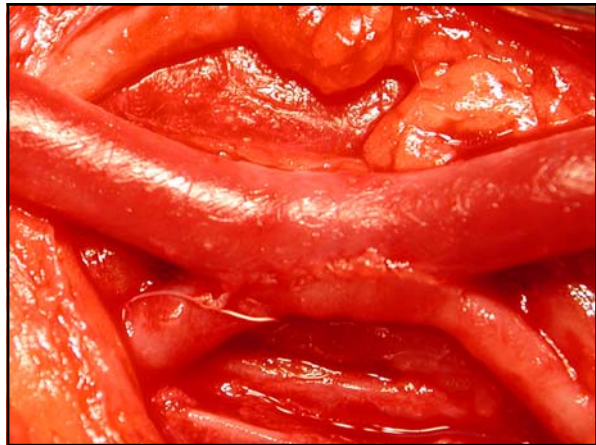
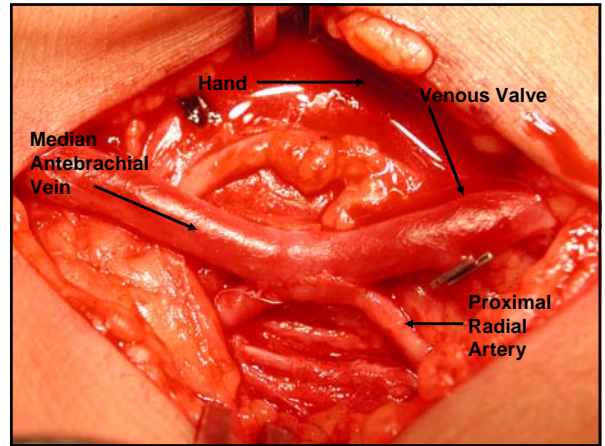
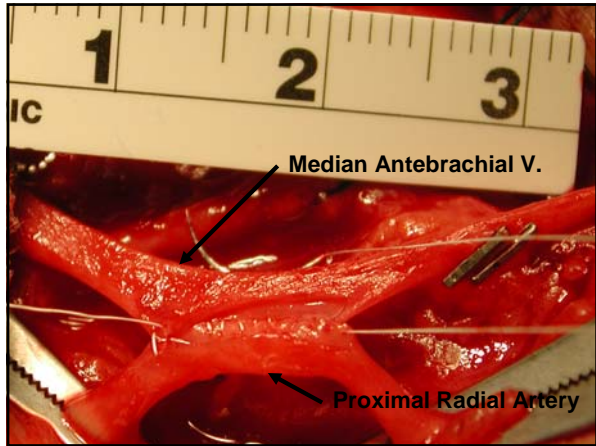


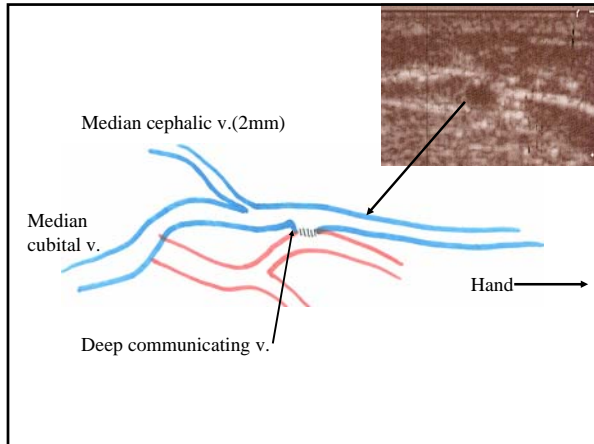
- Upper arm and forearm dialysis
- If one limb occludes the other remains open
- Ligation of major competitive outflow veins
- Reliable proximal radial artery inflow (no steal syndromes)
- Small incision, local+sedation, outpatient
- Excellent outcomes



Proximal Radial Artery AVF







Proximal Radial Artery AVFs
Postoperative evaluation

PRA AVF.....Past failed wrist AVF and upper arm graft

Arm swelling is not encountered

